

Comparison of radiographic assessments of the tibial plateau slope in dogs

Ermenegildo Baroni, DMV; Richard R. Matthias, BS; Denis J. Marcellin-Little, DEDV; Aldo Vezzoni, DMV; Martha E. Stebbins, DVM, PhD

Objectives—To evaluate the accuracy of 2 radiographic methods used to assess tibial plateau slope (TPS) in dogs and evaluate effects of film digitization and radiographic beam placement on TPS measurements.

Sample Population—16 hind limbs from dog cadavers weighing > 20 kg.

Procedures—Radiographs of tibiae were made with the radiographic beam centered over the stifle joint and midshaft of the tibia. Tibiae were collected, the femorotibial contact area was determined, and slope of the medial tibial condyle in relation to the tibial shaft was measured. Radiographs were digitized. Slope of the medial tibial condyle was measured on printed and digitized radiographs read in random order by 6 examiners unaware of anatomic measurements. Three examiners used a conventional measuring technique, and 3 examiners used an alternative measuring technique.

Results—Anatomic measurements were significantly higher than radiographic measurements made by use of the conventional interpretation method but did not differ from radiographic measurements made by use of the alternate method. Measurements from printed radiographs were lower than measurements from digitized radiographs for the 4 most experienced examiners.

Conclusions and Clinical Relevance—Measurements made by use of a line tangential to the cranial, linear portion of the medial tibial condyle at the femorotibial contact point were accurate measurements of the anatomic TPS. Measurements made by use of the conventional TPS measurement method underestimated the anatomic TPS. Measurements made on digitized radiographs were typically more accurate than measurements made on printed radiographs. (*Am J Vet Res* 2003;64:586–589)

Cranial cruciate ligament injuries are among the most common orthopedic problems in dogs.^{1,2} Multiple intra- and extra-articular surgical methods have been described³ to stabilize cranial cruciate-deficient stifle joints. The tibial plateau leveling osteotomy

(TPLO) is among the most popular methods used to treat cranial cruciate ligament injuries in dogs of large and giant breeds.^{4,5} Measurement of the tibial plateau slope (TPS) in relation to the tibial shaft is critical to the planning of a TPLO procedure. The conventional TPS measurement method, including patient positioning, radiographic view, and radiographic interpretation, have been described⁶ and used in several studies.⁶⁻⁸ In 2 reports,^{6,b} interobserver variability of this TPS measurement method was 4 and 5°, and intraobserver variability was 3°. With the conventional TPS measurement method, orientation of the medial tibial condyle is determined by tracing a line joining the small, discreet cranial margin of the tibial plateau and the point of insertion of the caudal cruciate ligament. However, that method has not been validated by comparing radiographic measurements to measurements made on bone, and rationale for the choice of these landmarks has not been provided. In our experience, gained from planning the treatment of angular tibial deformities with circular external fixators, our subjective impression is that the conventional radiographic method underestimates the slope of the plateau. On the basis of our findings, the actual slope of the cranial linear portion of the medial tibial condyle at the femorotibial contact point consistently appears steeper than the line defined by use of conventional landmarks. Therefore, we believe that landmarks for the conventional TPS measurement method do not define the plane of the contact surface between the femur and tibia. Rather, we believe that orientation of the proximal portion of the tibia would be better defined by tracing a line tangential to the cranial linear portion of the medial tibial condyle at the femorotibial contact point. That line could be used for an alternative TPS measurement method. Use of a TPS measurement method that would accurately determine the true orientation of the medial tibial condyle at the femorotibial contact point is logical and warranted, because the TPS is a measure of the shape of the main proximal articulating surface of the tibia and not a measure of the shape of nonarticulating portions of the tibia. Also, a method relying on the articulating surface of the bone would likely be less subjective and therefore, could have less interobserver and intraobserver variability than a method relying on nonarticulating landmarks.

The TPS measurement may be challenging because of the small size of the structures measured and because of suboptimal radiographic exposure. Radiograph digitization and software manipulation could be used to improve accuracy of TPS measure-

Received July 12, 2002.

Accepted December 4, 2002.

From the Departments of Clinical Sciences (Matthias, Marcellin-Little) and Farm Animal Health and Resource Management (Stebbins), College of Veterinary Medicine, North Carolina State University, Raleigh, NC 27606; the Clinica Veterinaria Baroni, via Martiri di Bellfiore 69/d, 45100 Rovigo, Italy (Baroni); and the Clinica Veterinaria, via Massarotti 24, 26100 Cremona, Italy (Vezzoni).

The authors thank Drs. David J. DeYoung, Lenore Anderson Mohammadian, Sammy Ramirez, and Simon C. Roe for technical assistance.

Address correspondence to Dr. Marcellin-Little.

ment through magnification, enhanced radiographic exposure, and use of digital goniometry. Digital radiography and digitized radiographs have been used in veterinary radiology.⁹ Digital radiography was found to be less accurate than conventional radiography for diagnosis of orthopedic problems in humans in certain instances but not in others.¹⁰⁻¹² To our knowledge, specific use of digital radiography or digitized radiographs to assess orthopedic problems in dogs has not been reported.

The purpose of the study reported here was to assess the accuracy of conventional and alternative TPS measurement methods and evaluate effects of radiograph digitization and beam position on TPS measurement in dogs. We hypothesized that the alternative TPS measurement method would be more accurate than the conventional TPS measurement method. We also hypothesized that TPS measurements made manually on printed radiographs would differ from TPS measurements made on digitized radiographs by use of image analysis software, and that radiographic beam position would influence TPS measurements.

Materials and Methods

Animals—Sixteen adult dogs weighing > 20 kg that had been euthanized for reasons independent from this study were included in the study. Sample size was determined before the study by conducting a statistical power analysis (projected difference between groups, 20%; type 1 error, 0.05; type 2 error, 0.8) to determine the minimal number of limbs necessary to conduct statistical comparisons between study groups. Immediately after euthanasia, the stifle joints were palpated. Presence and amount of cranial drawer movement, crepitus, joint effusion, periarticular fibrosis, or patellar luxation were recorded. Range of motion of stifle joints in flexion and extension were each measured 3 times.¹³ Dogs were excluded from the study if radiography revealed skeletal immaturity.

Radiographic methods—One hind limb per dog was randomly chosen. The stifle and tarsal joints were placed at 90° angles. The greater trochanter, lateral condyle, and lateral malleolus were placed in contact with the table. The opposite limb was slightly displaced cranially to avoid overlap of the stifle joints. Tabletop mediolateral radiographs were taken with an intensity ranging from 5 to 10 mA and penetrability ranging from 49 to 51 kilovolt (peak, kV[p]). A radiograph of the tibia was taken with the beam centered over the stifle joint (Fig 1). Radiographs were excluded from analysis if the femoral condyles were separated caudally, distally, or cranially by ≥ 2 mm. Dogs were kept in the same position, and a second radiograph was taken with the radiographic beam centered over the midshaft of the tibia.

Radiographic interpretation—Radiographs were digitized with a radiographic scanner.^c Six examiners independently read the printed and digitized radiographs in random order.¹⁴ Examiners were unaware of dog number, position of the radiographic beam, and anatomic measurements. Three examiners used the conventional TPS measurement method.^a One examiner was a resident in surgery with > 10 years of experience reading radiographs, and 2 examiners were residents in radiology with < 10 years of experience reading radiographs. These examiners compared the orientation of a line joining the small, discrete cranial margin of the tibial plateau and the point of insertion of the caudal cruciate ligament to a line joining the intercondylar eminence and a point equidistant to the

cranial and caudal aspects of the trochlea of the talus (Fig 1).⁶ Three examiners, all board-certified surgeons with > 10 years of experience reading radiographs, read radiographs by use of the alternative method. For the alternative method, TPS was measured by comparing the orientation of a line tangential to the linear portion seen on the cranial portion of the medial tibial condyle to the line joining the intercondylar eminence and a point equidistant to the cranial and caudal aspects of the trochlea of the talus (Fig 1). The 3 examiners who used the conventional method were familiar with the guidelines used for that method and unaware of the alternative method. The 3 examiners who used the alternative method had not been trained to use the conventional method. Examiners used a single method, because if they had used both methods, experience gathered by use of the first method may have influenced their findings during use of the second method.

For printed films, examiners superimposed transparent acetate sheets on radiographs, outlined the functional axis of the tibia and TPS, and made goniometric measurements with a transparent, plastic goniometer^d that had 1° gradations. For digitized films, axes were drawn and measured to the nearest 0.1° by use of image analysis software.^e The duration necessary to measure TPS on printed and digitized radiographs was recorded.

Anatomic measurements—Limbs were disarticulated, and skin and muscles were removed. Stifle joints were opened, and degenerative joint disease (DJD), cranial cruciate ligament, and meniscal damage were recorded. Limbs were disarticulated at the stifle joint. The distal portion of the limbs was mounted on a stand with the tarsus fixed at a 90° angle. Markers were used to highlight cranial and caudal aspects of the trochlea of the talus and the intercondylar emi-

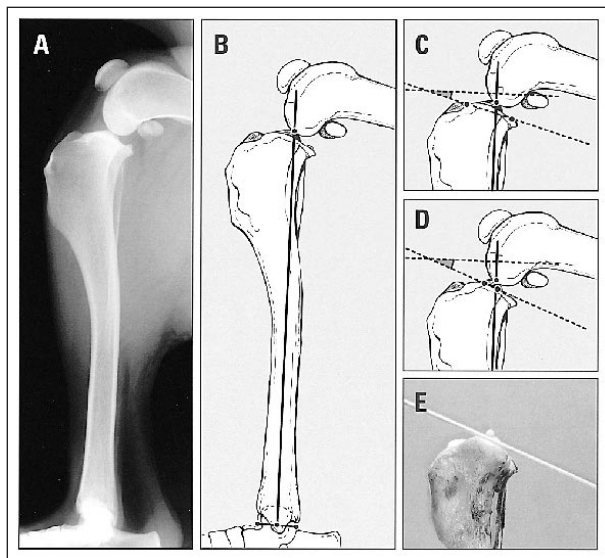


Figure 1—Mediolateral radiographic view (A), illustrations (B, C, D), and photograph (E) of a tibia and stifle joint in a dog. Femoral condyles are superimposed. Tibial plateau slope (TPS) is conventionally measured by comparing orientation of the functional axis of the tibia defined as the line joining the intercondylar eminence and a point equidistant to the cranial and caudal aspects of the trochlea of the talus (B) and the axis of the medial tibial condyle defined as the line joining the small, discrete cranial margin of the tibial plateau and the point of insertion of the caudal cruciate ligament (C). Alternatively, the axis of the medial tibial condyle may be defined as a line tangential to the cranial linear portion of the medial tibial condyle at the femorotibial contact point (D). The latter measurement more closely approximates the anatomic slope of the medial tibial condyle (E).

nence. The point of contact between the femur and tibia was determined from radiographs. A marker for orientation of the tibial plateau was placed at that point (Fig 1). Bones were digitally photographed with the center of the photograph placed at the level of the proximal portion of the tibia. The angle formed by the medial tibial condyle in relation to the line joining the intercondylar eminence and a point equidistant to the cranial and caudal aspects of the trochlea of the talus was measured by use of image analysis software.⁶ This measurement was repeated 5 times. The median value of these 5 measurements was used for statistical analysis.

Statistical analyses—Friedman ANOVA was used to determine differences between the median value of the 5 anatomic measurements and TPS measurements made on digitized radiographs for the 2 groups of examiners. Wilcoxon signed rank tests were used to determine differences between the TPS measurements on printed and digitized radiographs for each examiner.¹ Wilcoxon signed rank tests were used to compare TPS measurements made on radiographs with the radiographic beam centered over the stifle joint or midshaft of the tibia for each examiner. The mean interobserver variance and mean absolute deviation from the mean were calculated for printed and digitized radiographs read by use of the conventional and alternative TPS measurement methods. The duration spent reading printed radiographs was compared with the duration spent reading digitized radiographs by use of a paired Student *t* test. Differences were considered significant at $P < 0.05$.

Results

Sixteen dogs with weight ranging from 20 to 44 kg (median, 27 kg) were included in the study. One dog had DJD secondary to cranial cruciate ligament rupture. Mean \pm SD range of motion of the 15 stifle joints without DJD was $34^\circ \pm 3^\circ$ of flexion to $161^\circ \pm 2^\circ$ of extension.

The SD of the 5 anatomic measurements for all tibiae ranged from 0 to 2° (mean, 1°). Mean \pm SD (median) anatomic TPS measurements were $27^\circ \pm 3^\circ$ (26°). Mean \pm SD (median) radiographic measurements made by the 3 examiners on printed and digitized radiographs taken with the beam centered over the stifle joint or midshaft of the tibia by use of the alternative TPS measurement method ranged from $22^\circ \pm 5^\circ$ (21°) to $27^\circ \pm 5^\circ$ (27°) and did not differ significantly from anatomic measurements. Mean interobserver variance and mean absolute deviation from the mean for the alternative TPS measurement method were 8.6° and 2.0° , respectively, for printed films centered over the stifle joint, and 6.8° and 1.5° , respectively, for digitized films centered over the stifle joint. Mean \pm SD (median) radiographic measurements made by the 3 examiners on printed and digitized radiographs taken with the beam centered over the stifle joint or the midshaft of the tibia by use of the conventional TPS measurement method ranged from $16^\circ \pm 4^\circ$ (15°) to $24^\circ \pm 4^\circ$ (24°) and were significantly ($P < 0.001$) lower than anatomic measurements. Mean interobserver variance and mean absolute deviation from the mean for the conventional TPS measurement method were 16.5° and 2.7° , respectively, for printed films centered over the stifle joint, and 12.9° and 2.2° , respectively, for digitized films centered over the stifle joint. The TPS measurements from printed radiographs taken with the beam centered over the stifle joint differed from TPS measurements from

digitized radiographs taken with the beam centered over the stifle joint for the 4 most experienced examiners (3 examiners for the alternative TPS measurement method [$P = 0.001$ to 0.034] and 1 examiner for the conventional TPS measurement method [$P = 0.008$]) but not for the 2 least experienced examiners. The duration necessary to read printed radiographs (mean \pm SD, 3.0 ± 0.4 min/radiograph) did not differ from the duration necessary to read digitized radiographs (mean \pm SD, 4.2 ± 2.1 min/radiograph).

Mean \pm SD tibial length was $204 \text{ mm} \pm 21 \text{ mm}$. The TPS measurements from radiographs taken with the beam centered over the stifle joint differed from measurements taken with the beam centered over the midshaft of the tibia for 1 examiner reading printed films ($P = 0.034$) and another examiner reading digitized films ($P = 0.044$) but did not differ for the other measurements.

Discussion

The purpose of this study was to compare radiographic TPS measurements with anatomic TPS measurements of the portion of the tibia that articulates with the femur. Two TPS measurement methods were used. Because not all examiners read radiographs by use of both methods, no direct statistical comparisons of these methods were made. Rather, we compared results of 2 groups of reader-TPS measurement combinations with anatomic measurements.

The TPS measurements made by 3 examiners by use of the alternative method did not differ significantly from anatomic measurements. These findings are not unexpected, because that method uses landmarks identical to landmarks used for anatomic measurements. Mean interobserver absolute deviation from the mean of the alternative method was low (1.5° for digitized films and 2.0° for printed films). Intraobserver variability of the alternative method remains to be determined to fully assess its diagnostic value. When measuring TPS of dogs with stifle joint subluxation secondary to cranial tibial displacement caused by rupture of the cranial cruciate ligament, the femorotibial contact point may be altered. Whether the anatomic orientation of the cranial linear portion of the medial tibial condyle may be accurately determined in these subluxated stifle joints has not been investigated.

The TPS measurements made by 3 examiners by use of the conventional TPS measurement method were underestimations of the anatomic TPS as defined in this study. This suggests that measurements made by use of the conventional TPS measurement method do not accurately represent measurements of the proximal articulating surface of the tibia. Because the conventional radiographic method has been widely used to plan and assess TPLO procedures, the slope of the medial tibial condyles after these procedures may also have been underestimated. Mean difference between measurements made by the 2 methods in this study was 7° . The importance of a 7° underestimation of the orientation of the proximal tibial articulating surface is not known, but that underestimation may be of importance both clinically and when conducting biomechanical or biomodeling research.

Experience in reading radiographs appeared to influence radiographic TPS measurements. Differences between measurements made on printed and digitized films and differences between radiographs taken with the beam centered over the stifle joint and the midshaft of the tibia were detected for the 4 most experienced examiners, but not for the 2 least experienced examiners. This may have been the result of greater variability of TPS measurements made by less experienced examiners, compared with TPS measurements made by more experienced examiners. Experience also appeared to influence TPS measurements in another study.⁶

The TPS measurements made on digitized films were typically larger and closer to anatomic measurements than TPS measurements made on printed radiographs for the 4 most experienced examiners. Digital measurements may have been more precise than measurements from printed radiographs because of the ability to magnify the proximal portion of the tibia and adjust radiographic exposure. These adjustments may have facilitated identification of specific anatomic landmarks during TPS measurements. Results of this study suggest that routine digitization and analysis of digitized radiographs of tibiae would enhance the accuracy of TPS measurements in dogs.

When taking radiographs for TPS measurement, a midshaft radiographic beam placement may allow closer collimation and reduce radiation scatter compared with a stifle radiographic beam placement. Midshaft beam placement was used in a study comparing TPS in dogs with and without cranial cruciate ligament injuries.¹⁵ Midshaft beam placement did not appear to influence radiographic canine TPS measurements, compared with beam placement over the stifle joint in another report.^b In our study, however, TPS measurements from radiographs taken with the beam centered over the stifle joint differed from TPS measurements from radiographs taken with the beam centered over the midshaft of the tibia for 2 examiners. Difference in beam position between radiographs taken with the beam centered over the stifle joint and radiographs taken with the beam centered over the midshaft of the tibia was approximately half of the length of the tibia and therefore, ranged from 9 to 12 cm for tibiae used in this study. Changing beam position from the stifle joint to the midshaft of the tibia may have more influence on measurements made on long tibiae than on measurements made on shorter tibiae; however, this was not specifically tested in our study. Distal displacement of the radiographic beam from the elbow joint to the midshaft of the radius was found to influence the evaluation of the shape of the proximal portion of the

ulna in dogs.¹⁶ Whether displacement of the radiographic beam from the stifle joint to the midshaft of the tibia decreases the accuracy of TPS measurements for clinical patients remains equivocal.

^aSlocum B, Slocum TD. Tibial plateau measurement, Slocum Enterprises Inc, Eugene, Ore: Unpublished data, 2000.

^bReif U. Influence of limb positioning and interobserver variation on the measurement of the tibial plateau angle (abstr), in *Proceedings. Vet Orthop Soc* 2001;28:6.

^cLumiscan 75, Lumisys, Sunnyvale, Calif.

^d6-in goniometer, Zimmer Inc, Warsaw, Ind.

^eAdobe Photoshop 5.0, Adobe Systems Inc, Mountain View, Calif.

^fAnalyse-It, version 1.61, Leeds, England.

References

1. Arnoczky SP. Pathomechanics of cruciate ligament and meniscal injuries. In: Bojrab MJ, ed. *Disease mechanisms in small animal surgery*. 2nd ed. Philadelphia: Lea & Febiger, 1993;764–776.
2. Johnson JA, Austin C, Breur GJ. Incidence of canine appendicular musculoskeletal disorders in 16 veterinary teaching hospitals from 1980 to 1989. *Vet Comp Orthop Traumatol* 1994;7:56–69.
3. Patterson RH, Smith GK, Gregor TP, et al. Biomechanical stability of four cranial cruciate ligament repair techniques in the dog. *Vet Surg* 1991;20:85–90.
4. Slocum B, Slocum TD. Tibial plateau leveling osteotomy for repair of cranial cruciate ligament rupture in the canine. *Vet Clin North Am Small Anim Pract* 1993;23:777–795.
5. Watt P. Tibial plateau levelling. *Aust Vet J* 2000;78:385–386.
6. Caylor KB, Zumpano CA, Evans LM, et al. Intra- and inter-observer variability of tibial plateau slope from lateral radiographs in dogs. *J Am Anim Hosp Assoc* 2001;37:263–268.
7. Warzee CC, Dejardin LM, Arnoczky SP, et al. Effect of tibial plateau leveling on cranial and caudal tibial thrusts in canine cranial cruciate-deficient stifles: an in vitro experimental study. *Vet Surg* 2001;30:278–286.
8. Reif U, Hulse DA, Hauptman JG. Effect of tibial plateau leveling on stability of the canine cranial cruciate-deficient stifle joint: an in vitro study. *Vet Surg* 2002;31:147–154.
9. Tilley LP, Miller MS, Wortman JA, et al. Teleradiology in veterinary medicine. *Semin Vet Med Surg Small Anim* 1986;1:172–175.
10. Murphey MD. Digital skeletal radiography: spatial resolution requirements for detection of subperiosteal resorption. *Am J Roentgenol* 1989;152:541–546.
11. Wilson AJ, Hodge JC. Digitized radiographs in skeletal trauma: a performance comparison between a digital workstation and the original film images. *Radiology* 1995;196:565–568.
12. Calder LD, Maclean JR, Bayliss AP, et al. The diagnostic performance of a PC-based teleradiology link. *Clin Radiol* 1999;54:659–664.
13. Jaegger G, Marcellin-Little DJ, Levine D. Reliability of goniometry in Labrador Retrievers. *Am J Vet Res* 2002;63:979–86.
14. Snedecor GW, Cochran WG. *Statistical methods*. 7th ed. Ames, Iowa: Iowa State University Press, 1980;463–466.
15. Morris E, Lipowitz AJ. Comparison of tibial plateau angles in dogs with and without cranial cruciate ligament injuries. *J Am Vet Med Assoc* 2001;218:363–366.
16. Murphy ST, Lewis DD, Shiroma JT, et al. Effect of radiographic positioning on interpretation of cubital joint congruity in dogs. *Am J Vet Res* 1998;59:1351–1357.